Dermoid Tumors of the Ovary: Evaluation of the Gasless Lift-Laparoscopic Approach

DANIEL KRUSCHINSKI, M.D.
MEDICAL DIRECTOR
ENDOSCOPIC GYNECOLOGY CENTERS
ROTTHALMÜNSTER, GERMANY

SWAPNIL LANGDE, M.D.
ASSISTANT SURGEON
ENDOSCOPIC GYNECOLOGY CENTERS
ROTTHALMÜNSTER, GERMANY

SHIRLI HOMBURG, PH.D.
SCIENTIST
ENDOSCOPIC GYNECOLOGY CENTERS
ROTTHALMÜNSTER, GERMANY

ANUPAM KAPUR, M.D.
ASSISTANT SURGEON
ENDOSCOPIC GYNECOLOGY CENTERS
ROTTHALMÜNSTER, GERMANY

ABSTRACT

Laparoscopic removal is widely accepted as the treatment of choice for dermoid tumors. However, the spillage of dermoid content with the laparoscopic approach is very high compared to laparotomy. The potential malignancy of dermoid tumors and the rare, but difficult to treat, chemical peritonitis in cases of spillage of dermoid content should lead to an adaptation of procedures during an endoscopic operation on a dermoid tumor to comply with the precautions of the "open" technique. Lift-laparoscopy combines laparoscopy with the standard procedures of laparotomy and thus may help reduce the spillage of dermoid contents. In a retrospective study of 108 patients with dermoid tumors, the frequency of the rupture of a dermoid tumor during a lift-laparoscopic operation was examined. Among the 79 cases of organ-preserving treatment, there were only three cases (3.8%) where a rupture of the dermoid capsule occurred. Even in cases of ruptures, it was possible to avoid spillage by closing the lesion with a clamp and continue the enucleation of the dermoid tumor during a lift-laparascopic operation. After thorough abdominal cavity lavage, none of these three cases showed a cytological contamination of the abdominal cavity with dermoid cells. None of the ovariectomy or adnexectomy cases showed a rupture. Histologically, there was also no carcinoma in any of the examined dermoid tumors. By adapting the endoscopic dermoid surgery to the precautions established in an open surgery technique using gasless lift-laparoscopy, ruptures and cell spilling can be avoided to a large extent but not completely excluded. Compared with other methods, the number of ruptures and spillage of dermoids by organ-preserving treatment as well as ovariectomy is lowest using a lift-laparoscopic procedure.

INTRODUCTION

Mature cystic teratomas, commonly called dermoid cysts, are the most common benign germ cell tumors of the ovary in women of reproductive age.[1] Future fertility is a major concern among these women; therefore, the surgical management must focus on preserving ovarian tissue. All peri- or postmenopausal patients should undergo an oophorectomy. Transvaginal ultrasound plays a decisive role in pre-operative diagnostics.[2–4] A dermoid tumor can be diagnosed in most cases preoperatively by means of transvaginal ultrasound, as a result of which the operative management can be planned. Pre-operative ultrasound is extremely important also with regard to the bilateral occurrence of dermoid tumors in 10% to 20% of cases.[5] Patients requiring surgery should be appropriately counseled about the risks and benefits of laparoscopy and laparotomy, especially with regard to the risks of rupture and the spillage of dermoids, which is lower in laparotomies.[6] Ruptures and spillage of dermoid cells can lead to granulomatous peritonitis, chemical peritonitis, and by malignant transformation of dermoids to the intraperitoneal spread of cancer.[7–9] In the past, the primary puncture and suction or morcellation of dermoid tumors during the laparoscopic procedure with subsequent lavage of the abdominal cavity was recommended to avoid chemical peritonitis, especially when dealing with a teratomata of the ovary, which are malignant in up to 2% of cases.[10–12] The prevalence of postoperative adhesions can also be reduced by lavage. Later, special "endobags" were developed for laparoscopy to remove dermoids intact. However, the numbers of rupture and spillage during conventional CO_2-laparoscopic procedures are still high.

Because of the possibility of peritonitis and the malignant potential of dermoid tumors, a special type of surgical technique should be introduced into endoscopic surgery, one which, if possible, avoids ruptures and the contamination of the abdominal cavity with dermoid contents completely. As a consequence of this technique, the laparoscopic surgical procedures should comply with the advantageous open-surgery strategies of avoiding cell spilling to conform with the trend of performing minimally invasive operations.

The aim of this study was to examine the gasless lift-laparoscopic operation techniques on dermoid tumors with regard to the risk of rupture and possible contamination of the abdominal cavity with tumor contents. Lift-laparoscopy combines laparoscopy with the standard procedures of laparotomy and thus may help reduce the spillage of dermoids.

MATERIAL AND METHODS

Between 1992 and 2004, 108 patients with unilateral dermoid tumors were operated upon using the gasless lift-laparoscopic procedure: 79 premenopausal patients underwent an organ-preserving surgery by enucleation of the tumor, and 29 peri- and postmenopausal patients had an ovariectomy or adnexectomy by lift-laparoscopy. The preoperative ultrasound examination was carried out with a 5-MHz sector-vaginal scanner. For the gasless lift-laparoscopy, we used the Abdo-Lift™ Abdominal Wall Retractor (EndoSurgery Ltd., UK & Germany) without CO_2-insufflation. All operations were carried out according to a standardized method and documented on videotape during the entire operation.

First, the abdominal cavity was inspected and a rinse cytology was taken from the Douglas pouch. Next, the surface of the ovary was incised with a scalpel (Fig. 1), and the capsula was opened using a Metzenbaum's scissors (Fig. 2). The next steps were to strip the ovarian capsule carefully (Fig. 3) until the whole tumor was peeled off (Fig. 4) and, after coagulation of the basis with a bipolar forceps, dissected from the ovary (Fig. 5). Moreover, for this method special laparoscopic equipment was not needed at all—only conventional surgical instruments, which were inserted through appropriate incisions. To retrieve the dermoid from the abdomen, the endobag carrying the tumor (Fig. 6) was partly pulled out via a supra-symphysial incision in such a way that the edge was outside the abdominal wall and the dermoid remained under the surface. Its capsule was then incised in the endobag and the liquid tumor contents were aspirated

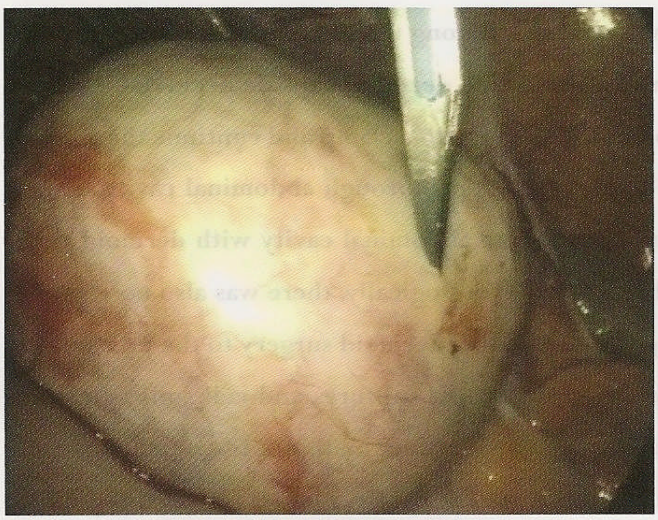

Figure 1. Incision of the ovarian capsula with an scalpel.

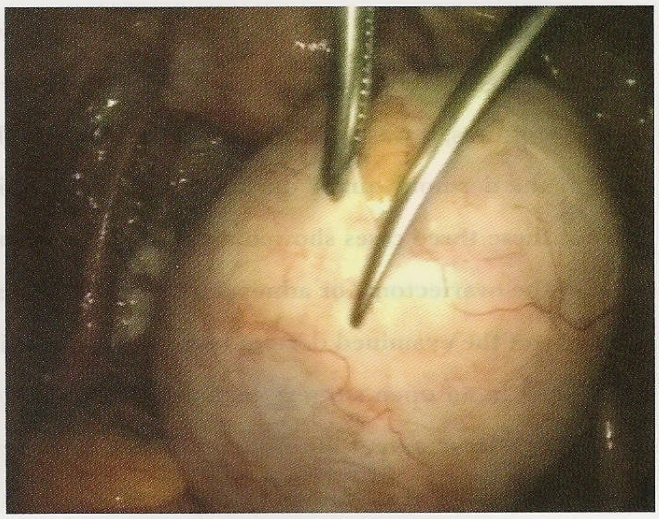

Figure 2. The ovarian capsula was incised with scissors.

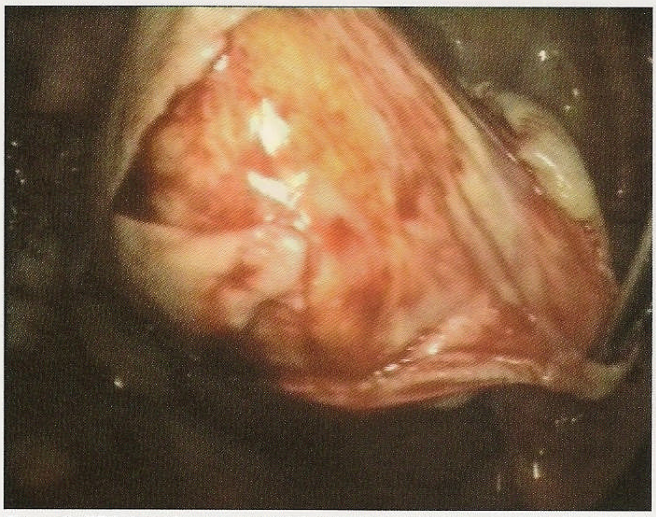

Figure 3. With two clamps, a careful stripping of the ovarian capsula was very easy to perform.

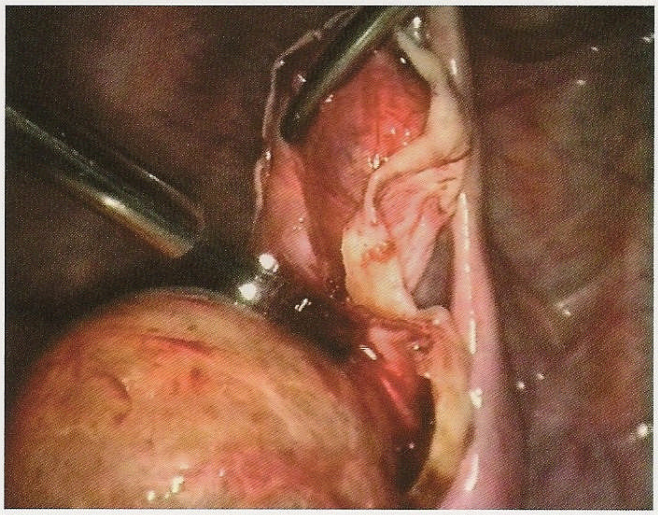

Figure 4. The base of the dermoid was coagulated and then dissected from the ovary.

with an additional suction tube until the tumor was reduced to a size that could be extracted. After retrival, the dermoid was opened to view the contents, which in this case consisted of hairs (Fig. 7). The suture for the obligatory reconstruction of the ovary was performed with monophile material of thickness 4 0 (Fig. 8) and extracorporeal knoting (Fig. 9). After finishing the last step of the operation, a rinse cytology was taken and an abdominal lavage was carried out with body-warm Ringer's lactate solution. Finally, a Robinson's drain was inserted. Figure 10 shows the final anatomical positions after the enucleation of the dermoid.

Cases of adnexectomies were performed in this way, that the infundibulopelvicum and ovarii proprium ligaments were coagulated and then dissected with the bipolar scissors. The retrival of the specimen was performed with an endobag as described previously. All removed dermoids were examined macroscopically and histologically for ruptures.

RESULTS

Of the 108 dermoid tumor patients, 79 patients were treated using organ-preserving methods and 29 patients underwent an ovariectomy or adnexectomy with tumor retrieval in the endobag afterward. The 79 premenopausal patients who underwent organ-preserving surgery by enucleation of the dermoid were between 12 years and 46 years of age, and the 29 peri- and postmenopausal patients with ovariectomy or adnexectomy were between 39 years and 56 years of age. The mean tumor size amounted to 5.1 cm (range: 3.1 cm to 9.4 cm) in the premenopausal group and 5.3 cm (range: 3.3 cm to 10.1 cm) in the postmenopausal group. In patients with an ovariectomy or adnexectomy, there was no rupture in any of them. In patients with ovarian preservation, 76 of the dermoids (96.2%) were successfully removed without rupture. In the three instances (3.8%) of rupture, a closure of the capsule with a clamp and a care-

Figure 5. The intact dermoid was retrived from the abdomen using an endobag.

Figure 6. The endobag was opened and the dermoid was inserted into the endobag.



Figure 7. After retrival, the dermoid was opened to view the contents, which in this case consist of hairs.

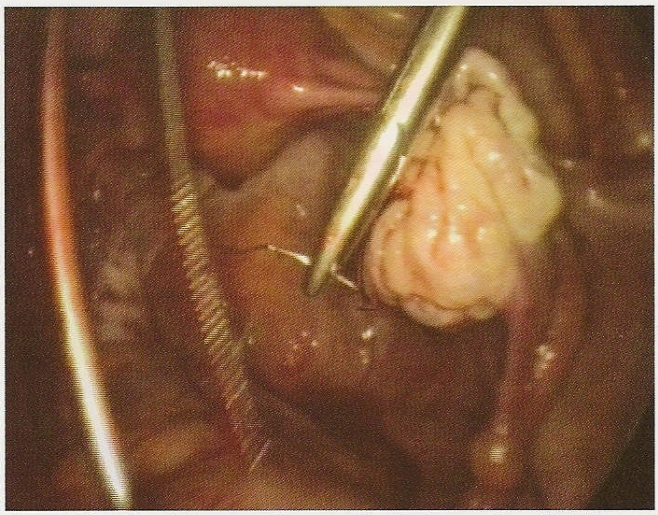

Figure 8. Suturing of the ovary with conventional sutures and needle holder.

ful preparation avoided further expansion of the lesion. Rinsing with several liters of body-warm Ringer's solution helped avoid spillage also in these cases, as the cytology at the end of the procedure did not show any spillage of cells. The dermoids were retrieved by means of an endobag as a matter of routine through the supra-symphysial incision, which had a width of 1 cm. In 12 patients, the dermoid contained bone portions, so we had to enlarge the supra-symphysial incision to about 2 cm before salvaging the tumor. In no patient did histology produce evidence of a teratoma. Rinse cytology, examined for contamination after the last surgical step and normally prior to abdominal lavage (except in the case of rupture, where it was taken after lavage), was always negative. Even in the patient where a capsule rupture occurred, no dermoid cells were found at the end of the operation. The average operation time was 53 min (range: 41 min to 73 min) in the organ-preservation group and 51 min (range: 43 min to 72 min) in the organ-removing group. Postoperative complications did not occur in any case. The patients were discharged after an average hospital stay of 3 days (range: 1 day to 6 days).

DISCUSSION

In treating dermoid tumors laparoscopically, the potential malignancy with the possible seeding of malignant cells should be taken into consideration. The rate of peritonitis after ruptures of dermoids also shows that new techniques and standards must be developed to minimize these complications. Our study shows that it is possible to minimize these risks by means of the gasless laparascopy. In the group of cystectomies with ovarian conservation (premenopausal women), in only 3.8% of the cases ruptures were diagnosed. In the group of postmenopausal women who were treated with adnexectomy, there were none. However, thanks to the immediate closing of the ruptures with clamps, spillage could be avoided among premenopausal women as well as among postmenopausal women. In studies comparable to those in which dermoids were operated on with con-

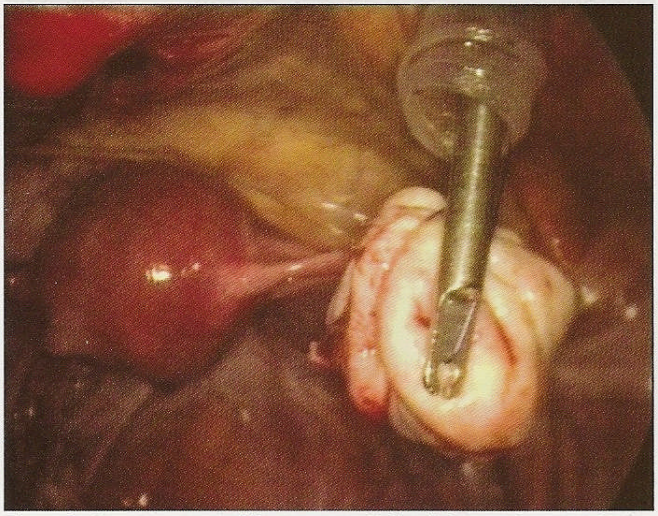

Figure 9. An extracorporeal knot was applied and the ovarian capsula was closed.

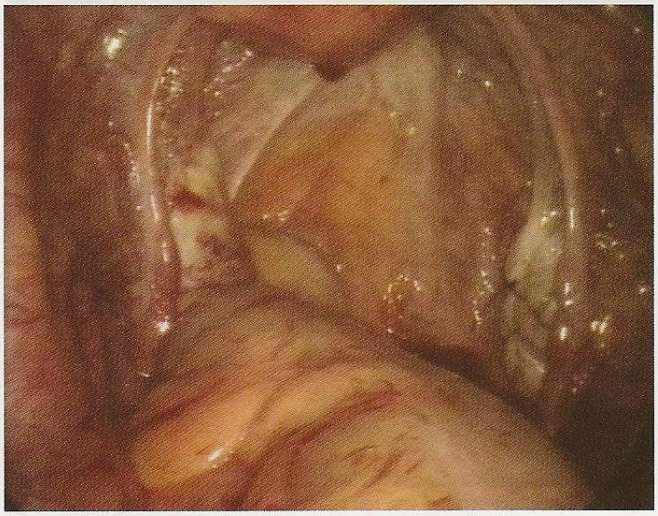

Figure 10. Final anatomical positions after dermoid enucleation. .

ventional CO_2-laparoscopy, recognizably worse results were achieved: Berg et al. reported a 66% rate of spillage by laparoscopic cystectomy with ovarian conservation and 24% with adnexectomy. In most cases, all dermoids were operated on by means of endobags.[13] Zanetta et al. even showed a spillage rate of 88% with ovarian preservation. In these studies, the dermoids were also removed with endobags.[14] Nezhat et al. showed that the use of endobags had a decisive impact on the spillage rate: 62% without endobags and 13.6% with endobags.[15] Surely, the most important advantage of the gasless laparoscopic removal of dermoids is that one can work with conventional instruments, which are shorter than those used for CO_2-laparoscopy. Because of the lower leverage, the surgeon is able to work with more sensitivity and thus a subsequent reduction of the spillage rate is possible. With some practice, it is relatively easy to dissect a dermoid intact with its solid capsule. This practice is an explanation for the shorter operation times (51 min and 53 min) compared to other authors, who note an average operation time of 73 min to 125 min for the CO_2-laparoscopy.[16–18]

Laparoscopic operations on dermoids should only be performed by experienced laparoscopists, and only with frozen sections. The contralateral ovary should be inspected most carefully for a bilateral dermoid. The patient must be informed about the risks and consequences of a possible cell contamination and the further procedure in case of malignancy. The possibilities of contamination can also be reduced considerably by lining the true pelvis with a big retrieval bag, or by the "diaphragma-method" described by Volz et al.[19] If rupture occurs, the contamination of the abdomen with dermoid contents can be reduced by lavage with rinse solution.[20] Furthermore, cell implants are reported to be reduced significantly by adding heparin.[21] Rinse cytology before and after completing every manipulation gives information about contaminaton of the abdominal cavity with tumor contents. Regarding oncological operating standards, primary punctures or even primary morcellation of a dermoid should be made obsolete.

CONCLUSION

Clear ultrasound criteria to exclude laparoscopic surgery as well as obligatory retrieval of dermoids in an endobag reduces the risk of unintentional operation on an unexpected malignancy. Peri- and postmenopausal patients should always be treated by ovariectomy, retrieving the preparation in an endobag. The laparoscopic surgery of dermoid tumors should be taught and standardized to achieve reliable standards of oncological surgery in cases of organ-preserving operations on premenopausal patients, so that the risk of tumor cell spilling arising from an "untidy" operating technique can be avoided. Carbon dioxide is also suspected to cause an increased implantation rate of tumor cells.[22] Endoscopists performing conventional laparoscopic surgery on dermoids with CO_2-pneumoperitoneum must pay particular attention to the precautions in comparison with gasless lift-laparoscopy, which combines the advantages of conventional and laparascopic surgery and has a low spillage rate. This method reduces postoperative adhesion formation and the spillage of tumor cells in case of malignancy, and is therefore an ideal surgical option for minimal invasive surgery in dermoid cases. STI

REFERENCES

1. Templeman CL, Fallat ME, Lam AM, et al. Managing mature cystic teratomas of the ovary. Obstet Gynecol Surv 2000;55:738-45.
2. Laing FC, Van Dalsem VF, Marks WM, et al. Dermoid cysts of the ovary: their ultrasonic appearances. Obstet Gynecol 1981;57:99-104.
3. Sheth S, Fishman EK, Buck JL, et al. The variable sonographic appearances of ovarian teratomas: correlation with CT. Am J Roentgenol 1988;151:331-4.
4. Bronshtein M, Yoffe N, Brandes JM, Blumenfeld Z. Hair as a sonographic marker of ovarian teratomas: Improved identification using transvaginal sonography and simulation model. J Clin Ultrasound 1991;19:351.
5. Novak ER, Woodruff JD. Novak's gynaecologic and obstetrics pathology with clinical and endocrin relations (8th ed.). Philadelphia: WB Saunders, 1979.
6. Yuen PM, Yu KM, Yip SK, et al. A randomized prospective study of laparoscopy and laparotomy in the management of benign ovarian masses. Am J Obstet Gynecol 1997;177: 109-14.
7. Huss M, Lafay-Pillet MC, Lecuru F, et al. Granulomatous peritonitis after laparoscopic surgery of an ovarian dermoid cyst. Diagnosis, management, prevention, a case report. J Gynecol Obstet Biol Reprod 1996;25:365-72.
8. Clement D, Barranger E, Benchimol Y, Uzan S. Chemical peritonitis: a rare complication of an iatrogenic ovarian dermoid cyst rupture. Surg Endoscop 2003;17:658.
9. Wang PH, Yen MS, Juang CM, et al. Intraperitoneal cancer spread after laparoscopic cystectomy for mature teratoma with malignant transformation. Eur J Gynaecol Oncol 2002;23: 131-2.
10. Nezhat C, Winer WK, Nezhat F. Laparoscopic removal of dermoid cysts. Obstet-Gynaecol 1989;73:278-81.
11. Chapron C, Dubuisson JB, Samouh N, et al. Treatment of ovarian dermoid cysts. Place and modalities of operative laparoscopy. Surg Endosc 1994;8:1092-7.
12. Crouet H, DeRanieri E, DeRanieri J. Secondary cancers arising in mature benign cystic teratomas of the ovary (dermoid cysts). J Gynecol Obstet Biol Reprod 1986; 15:1055-66.
13. Berg C, Berndorff U, Diedrich K, Malik E. Laparascopic management of ovarian dermoid cysts. A series of 83 cases. Arch Gynecol Obstet 2002;266:126-9.
14. Zanetta G, Ferrari L, Mignini-Renzini M, et al. Laparoscopic excision of ovarian dermoid cysts with controlled intraoperative spillage. Safety and effectiveness. J Reprod Med 1999; 44:815-20.
15. Nezhat CR, Kalyoncu S, Nezhat CH, et al. Laparoscopic management of ovarian dermoid cysts: ten years' experience. JSLS 1999; 3:179-84.
16. Campo S, Garcea N. Laparascopic conservative excision of ovarian dermoid cysts with and without endobag. J Am Assoc Gynecol Laparos 5;1998:165-70.
17. Lin P, Falcone T, Tulandi T. Excision of ovarian dermoid cyst by laparoscopy and by laparotomy. Am J Obstet Gynecol 1995;173: 769-71.
18. Remorgida V, Magnasco A, Pizzorno V, Anserini P. Four years experience in laparoscopic dissection of intact ovarian dermoid cysts. J Am Coll Surg 1998;187:519-21.
19. Volz J, Köster S, Melchert F. Tumorasepsis in der organerhaltenden pelviskopischen Ovarchirurgie am Beispiel von Dermoidzysten. Zentralbl-Gynäkol 1994;116:571-6.
20. Fielder EP, Guzick DS, Guido R, et al. Adhesion formation from release of dermoid contents in the peritoneal cavity and effect of copious lavage: a prospective, randomized, blinded, controlled study in a rabbit model. Fertil Steril 1996 Apr;65(4):852-9.
21. Goldstein DS, Lu ML, Hattori T, et al. Inhibition of peritoneal tumor-cell implantation: model for laparoscopic cancer surgery. J Endourol 1993;7:237-41.
22. Volz J, Köster S, Weiss M, et al. Pathophysiologic features of a pneumoperitoneum at laparoscopy: a swine model. Am J Obstet Gynecol 1996;174:132-40.